

THE MIDFACE

FILLING, LIFTING, OR BLEPHAROPLASTY?

Fred Fedok describes the treatment options available to address the changes brought about by aging to the lower eyelid, lid-cheek junction and nasolabial folds

ABSTRACT

The optimal rejuvenation of the aging midface depends on an appreciation of the anatomic aspects of the undesirable characteristics as well as a facility in the several techniques useful in the

management of aging of the midface and lower eyelid. The dynamics of the aging process in the facial area include skin laxity, loss of support of the lower eyelid and soft cheek tissues, volume loss, and bone loss. The manifestations

of the aging processes are different in different age groups and among patients with variable underlying inherited characteristics. There is a role for the use of fillers, fat transfer, lifting procedures, and placement of implants. Patients'

most favorable outcomes are produced when the proper diagnosis is coupled with the best combination of techniques for each individual patient. There are several interventions available for the rejuvenation of the aging midface.

MANY PATIENTS SEEKING FACIAL rejuvenation begin their inquiry with concerns about jowls, platysma bands, and an unsightly neck. They describe sagging brows and upper eyelids, bags under their lower eyelids, excess skin in the lower eyelid region, and an undesirable shape to their lower eyelids. They rarely seek advice to directly address their midface except when the specific midface aging changes and remedies are pointed out to them. They do notice what they perceive as deepening nasolabial creases in part because of the media attention to the nasolabial folds in regard to fillers. The patients also notice a flattening and laxity to their midface structures but frequently have difficulty describing exactly what is causing these changes. Patients usually do not understand why their nasolabial sulci appear to have become deeper and that they have a less attractive lower eyelid region than they did a decade previously.

Until the late 80s and early 90s, there was a paucity of popular techniques used for the correction of midface aging. It was already quite clear that a traditional facelift did very little for the lid-cheek junction or even the nasolabial folds. It was recognized that the maximum desirable impact of a traditional facelift was usually along the jawline and in the neck. Although various cheek and submalar implants were available, they were not universally used. The nasolabial fold itself was 'attacked'



FRED FEDOK, MD, FACS
Fedok Plastic Surgery
Foley, AL, US

email: drfredfedok@me.com

with a contradictory repertoire of liposuction, excision, and placement of early 'fillers' and implants.

Catalyzed by the further knowledge and understanding of the descent of the midface structures that occurs with aging, there has been an expanding number of tools available to remedy various functional and cosmetic issues with the midface^{1,2}. These tools include surgical midface lifts of varying aggressiveness, advances in blepharoplasty to both correct eyelid position and to preserve a youthful eyelid shape, an ongoing spectrum of lower eyelid fat removal versus fat repositioning, the use of various malar and orbital rim implants, and the most recent adaptations of volume replacement using both autogenous fat and off-the-shelf fillers. The surface of the skin remains a separate issue, with rhytids and skin laxity frequently requiring an intervention directed at the skin surface to cause collagen contraction and skin tightening, such as lasers and radiofrequency devices.

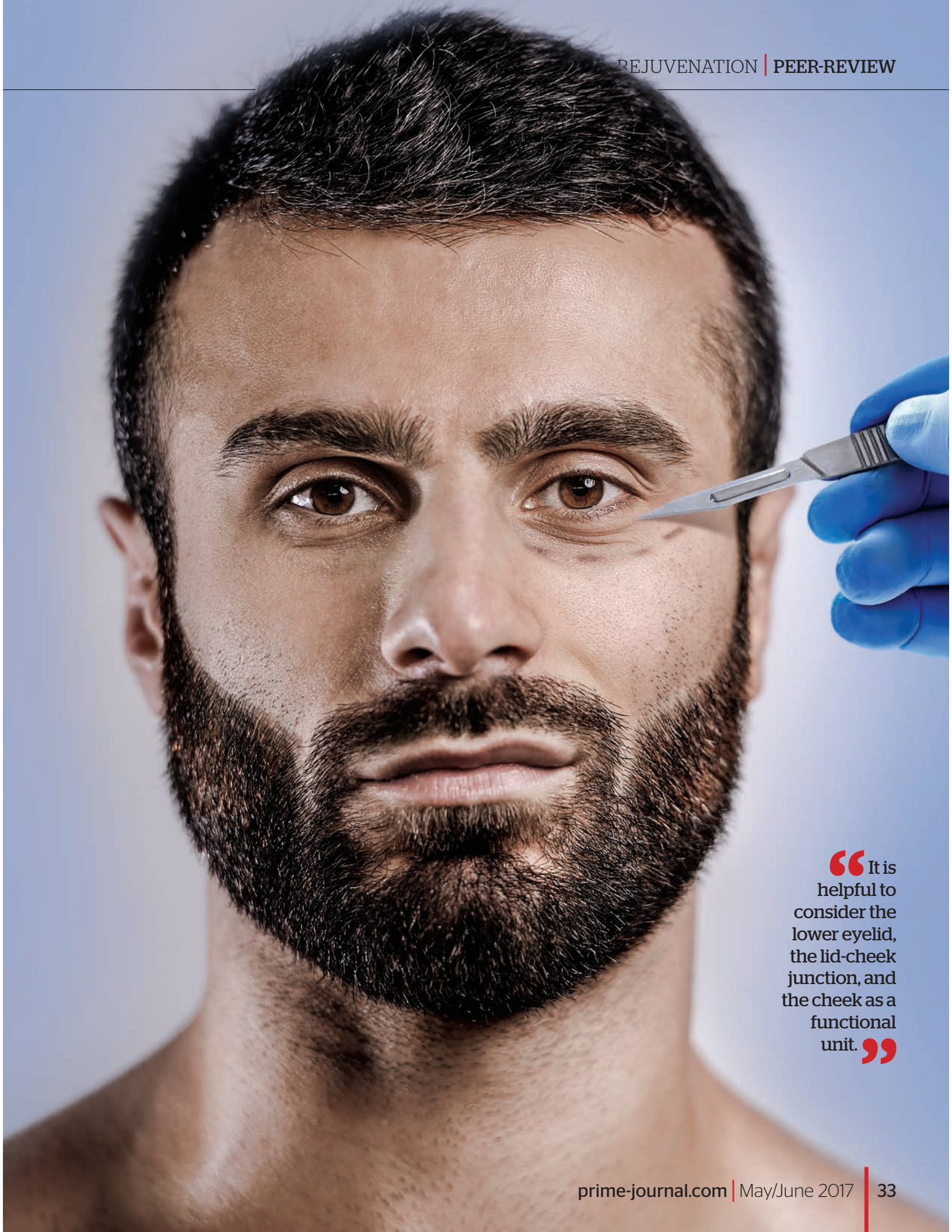Anatomy and age related changes to the midface

It is helpful to consider the lower eyelid, the lid-cheek junction, and the cheek as a functional unit. The movement and the structural integrity of the area are interrelated. Several simultaneous deleterious changes occur to this set of adjacent structures because of aging.

The various dynamic factors that appear to be behind midface aging include decreased skin elasticity and a relaxation of the cheek and orbital retaining ligaments, >

COVER
STORY

KEYWORDS
Midface, blepharoplasty, volume resoration, lifting techniques



“ It is helpful to consider the lower eyelid, the lid-cheek junction, and the cheek as a functional unit. ”

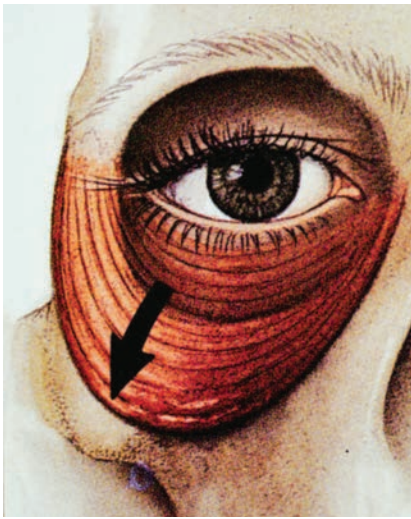


Figure 1 Rendering depicting aging changes of the lower eyelid and midface

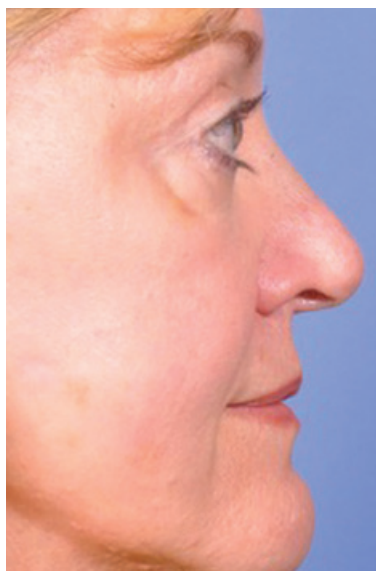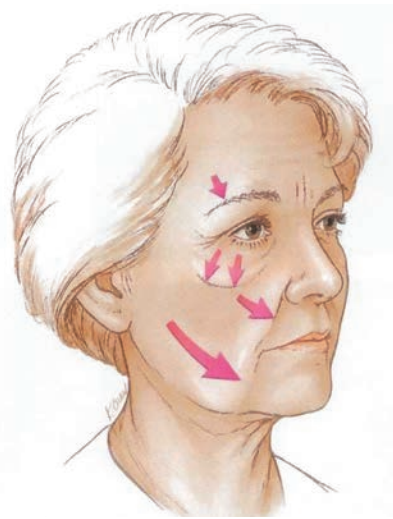


Figure 2 Image depicting characteristic double convexity deformity of lower eyelid and midface

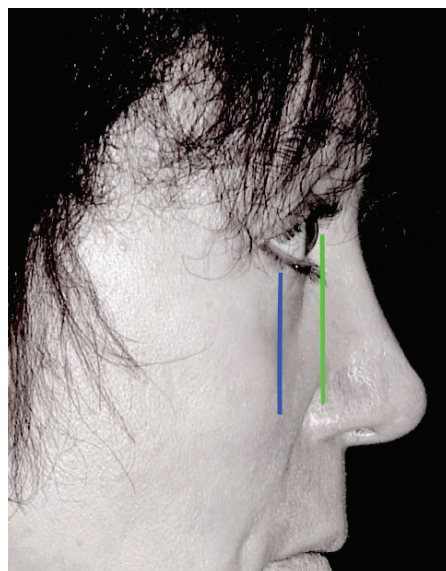


Figure 3 Rendering depicting 'negative vector' midface anatomy. Note the pupil projects far more anterior than the negative vector cheek projection

At the lid-cheek junction, a characteristic deformity develops that is referred to as the double convexity of the lower eyelid and midface junction (Figure 2). This double-convexity is produced by the changing relationship of the convexity of the pseudo-herniation of the orbital fat, the relative concavity caused by the skeletonizing of the orbital rim due to the descent of the suborbicularis oculi fat (SOOF) and cheek soft tissue, and the convexity of the now lower positioned cheek soft tissue mound. In youth and in the rejuvenated face, this anatomic region has smooth contours as there is a gradual transition of the lower eyelid contour across the orbital rim to the cheek. With age, these components are separated from each other and the different contours are more apparent.

These changes are accentuated or accelerated in patients who have a lack of skeletal projection to their orbital rim and midface

“With the recognition of the anatomic changes that occur with aging, the popularization of new techniques and the development of new biomaterials, the treatment of the midface has changed appreciably over the last decade.”

and are considered as having a negative vector midface relationship (Figure 3). These negative-vector patients have prominent, attractive eyes in youth, but exhibit characteristic midface aging more readily. There is less support for the periorbital structures and the patients appear to have the propensity to develop an unattractive bowing of their lower eyelids, skeletonization of the orbital rim, functional eyelid retraction, and ectropion.

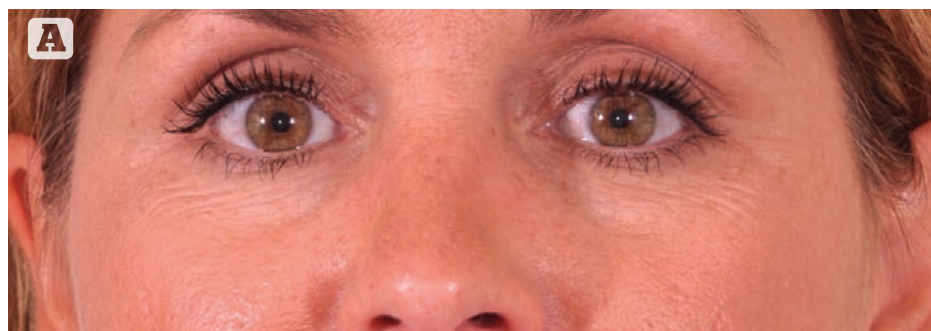In contrast, those patients with good midface skeletal projection or a positive vector relationship appear to have more support for the lower eyelid; in a sense, the projection acts as a functional shelf that the eyelid and associated structures rest on. The periorbital structures are, therefore, less prone to descend from decreased, age-related laxity of the retaining ligaments of the cheek.

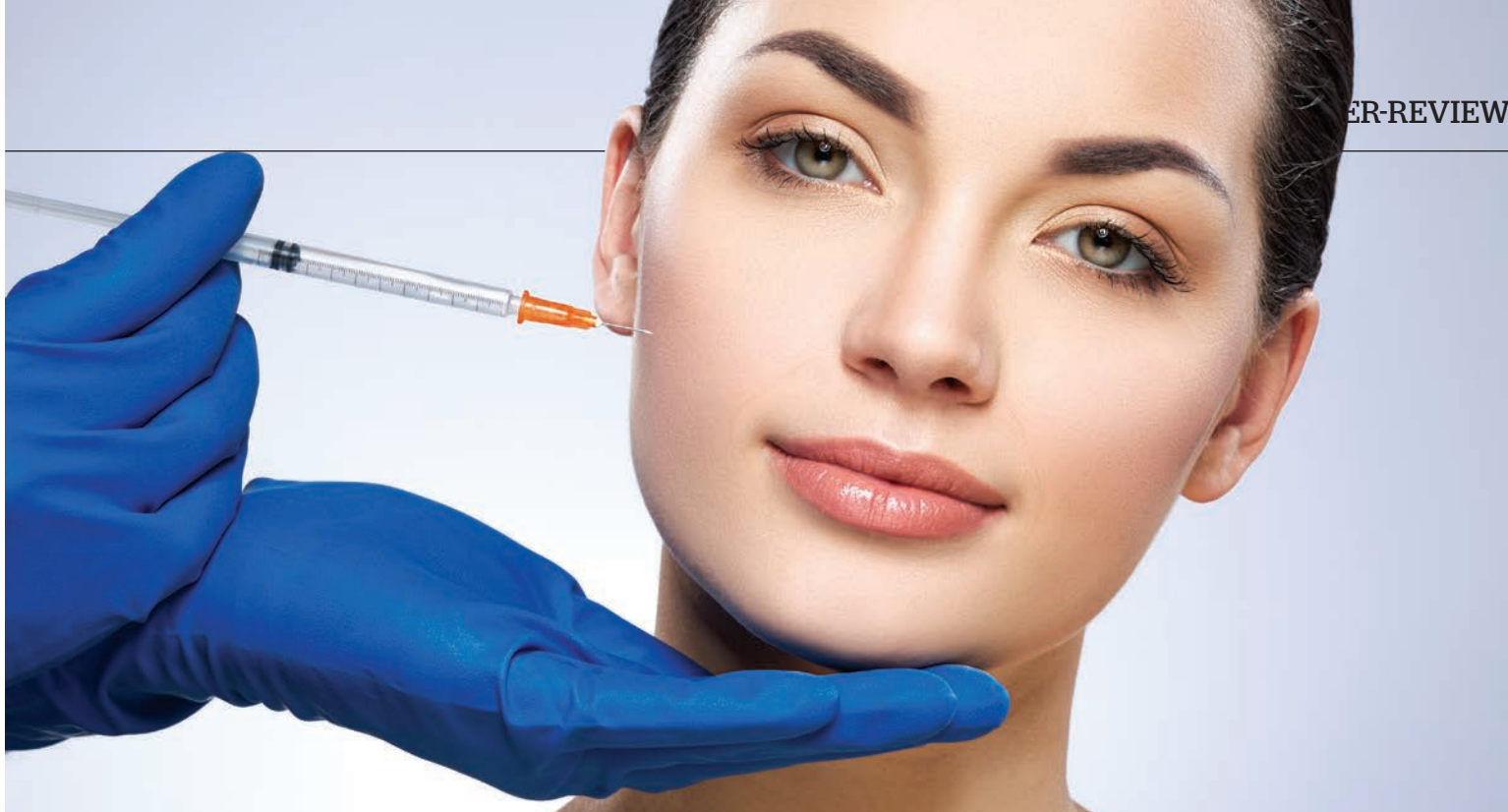Contemporary management of midface aging

With the recognition of the anatomic changes that occur with aging, the popularization of new techniques and the

▷ which comprise the connections to the skeleton, the underlying musculature, and the skin itself. There are also involuntional changes in the fat compartments of the midface caused by both diminishing support of the fat compartments as well as fat atrophy itself. All this occurs while the orbital rims themselves undergo a loss of bone and a structural loss of projection³.

As a result of these changes, there is a descent of the eyelid margin, the orbicularis muscle lengthens vertically thus producing festoons and the cheek fat pad, which normally is retained high along the midface skeleton, descends into a lower position (Figure 1). The nasolabial crease becomes more pronounced. While there is less of an actual deepening of the crease, as the fullness of the cheek mound descends to a position adjacent to the relatively fixed nasolabial crease, the contrasting convex and concave contours create the appearance of a deepening sulcus⁴.





development of new biomaterials, the treatment of the midface has changed appreciably over the last decade. This has resulted in a remarkable improvement in facial rejuvenation outcomes that were not achievable with traditional facelifting techniques. Due to the significant impact correction of this anatomic area has on overall facial rejuvenation, increased attention is now paid to the midface by facial rejuvenation surgeons. The contemporary cosmetic surgeon has a larger choice of tools to be used in response to the spectrum of anatomic abnormalities that is presented by the patient.

Restoration of volume

The restoration of volume has taken on a predominant role. The deflation of soft tissue and skeletonization, such as the tear trough deformity, is largely managed through the restoration of volume using both fat and fillers.

Patients are seeking correction at a younger age and volume restoration is frequently the first intervention to entertain. Mild and moderate abnormalities can be corrected adequately with either fillers or fat, and the achievable results are comparable to those possible with surgical techniques. The off-the-shelf fillers also add a compelling convenience factor⁵⁷. This non-surgical intervention can frequently be performed at a lower cost and reduced morbidity than a surgical intervention.

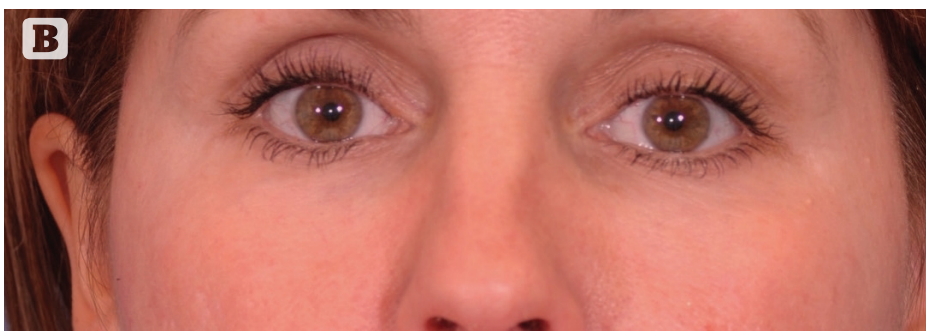“ In the midface and in the lateral cheek, an HA with more lifting characteristics and less spreading characteristics can be placed that is long-lasting and provides not only volume but also structural support⁶. These materials are usually placed deep, above the level of the periosteum. ”

The patients' anatomic abnormalities suggest what intervention to use for correction. For those with less severe abnormalities, corrections may only require a limited amount of strategic volume replacement. Some patients present with limited skin redundancy and rhytids, without eyelid malposition, limited lower eyelid fat bulging, limited skeletonization, and no appreciable malar dissent. In these patients, acceptable results can be obtained with the placement of volume along the orbital rim (*Figure 4*).

In a patient with more severe changes, with noticeable descent of the malar fat pad, the strategy of volume replacement is different. Volume is again placed along the orbital rim, but also to change the malar contour itself. Here the placement of volume is performed, in essence, to change the center of gravity of the cheek mound to a higher position. While the filler or fat expands the soft tissue envelope, a lifting of the malar mound occurs. A reduction of the apparent deepness of the nasolabial crease occurs along with an improved contour of the malar eminence. The carefully placed volume will fill-out the skeletonization of the orbital rim as well as the tear-trough deformity. Hyaluronic acid fillers (HA) that have good spreading characteristics and less lifting characteristics are ideal for placement in the area of the orbital rim. They provide volume without the need of skeletal support. They are relatively forgiving and self-smoothing so that they can be placed with limited risk of creating any lumps.

In the midface and in the lateral cheek, an HA with >

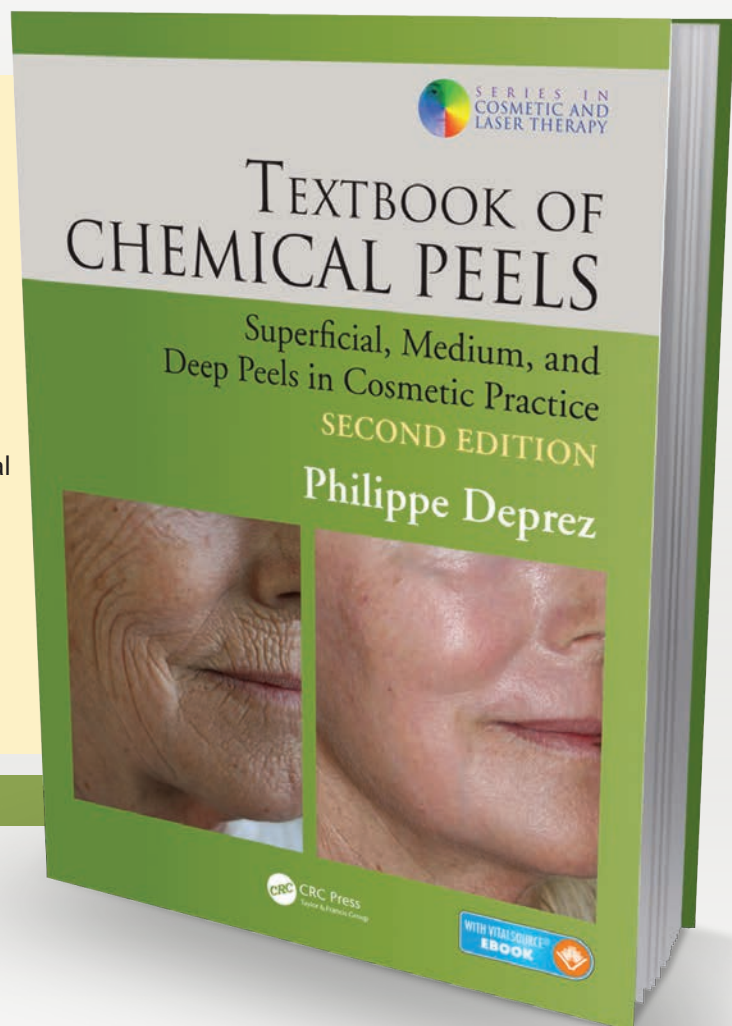
Figure 4 Clinical images of patient. A) Pre-procedure revealing characteristic tear trough deformity and skeletonization of orbital rim. B) After placement of HA filler along infraorbital rim to improve tear trough deformity and skeletonization of orbital rim



New edition of the definitive guide to all types of chemical peel treatments

- Based on the author's extensive experience in both research and practice,
- Reflects the new classification of peels as a medical, rather than cosmetic, treatment and helps providers by making chemical peel formulas easier, safer, and quicker to use.
- Includes new material on adjunctive procedures such as microneedling and mesotherapy, and explores mosaic peels
- Results are discussed for a variety of chemical peels including alpha hydroxy acids, trichloroacetic acid, salicylic acid, resorcine, and phenols.
- Incorporates color clinical photographs throughout, with a full chapter is devoted to discussing complications associated with chemical peels.

May 2016 • 393pp • 9781482223934 • £114.00



Order your copy today from

www.crcpress.com



CRC Press
Taylor & Francis Group

www.crcpress.com

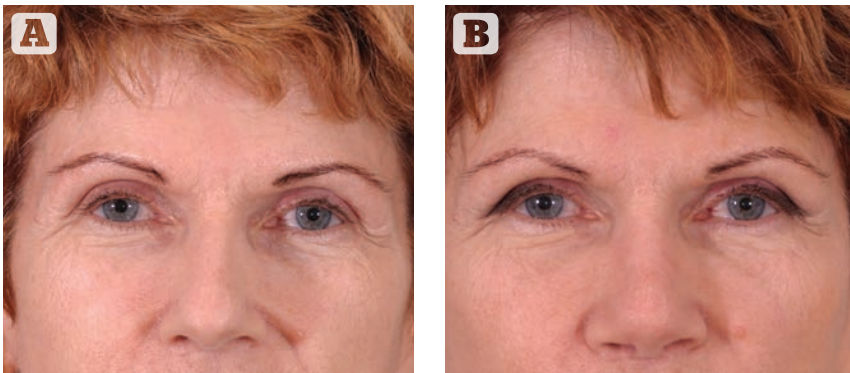


Figure 5 Clinical images of patient. A) Pre-procedure revealing characteristic tear trough deformity and significant descent of the malar soft tissue. B) After fat transfer to improve tear trough deformity and replacement of cheek volume

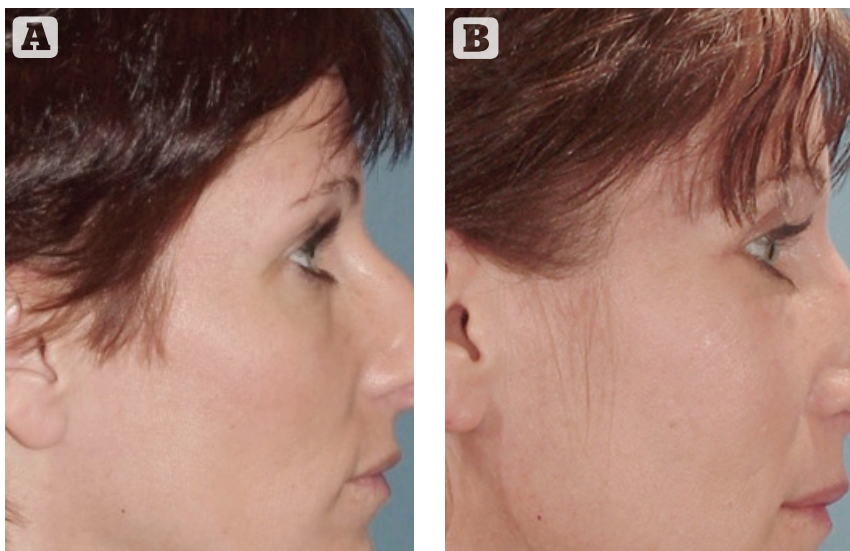

Figure 6 Clinical images of patient. A) Pre-procedure revealing characteristic tear trough deformity and skeletonization of orbital rim and significant descent of the malar soft tissue. B) After transtemporal/transpalpebral midface lift with correction of the double-convexity deformity and elevation of the cheek mound

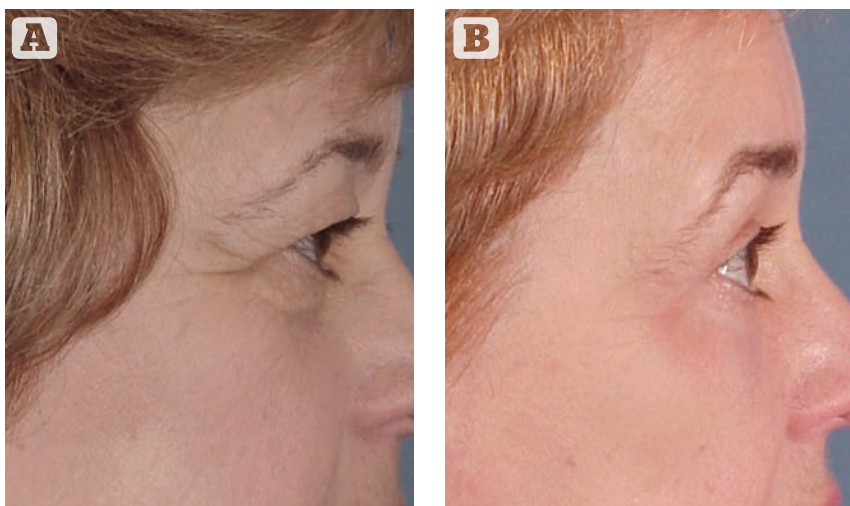

Figure 7 Clinical images of patient. A) Pre-procedure revealing characteristic tear trough deformity and skeletonization of orbital rim and significant underprojected orbital rim. B) After correction of negative-vector anatomy with the transconjunctival placement of porous polyethylene orbital rim implant and limited transpalpebral midface lift

▷ more lifting characteristics and less spreading characteristics can be placed that is long-lasting and provides not only volume but also structural support⁸. These materials are usually placed deep, above the level of the periosteum. With proper appreciation of the anatomy and technique of application, this can be achieved safely with the minimal risk of morbidity and complication.

Autogenous fat can be placed similarly in the cheek area (Figure 5). When placed deeply, it becomes easy to perform

“If patients have a large amount of bulging orbital fat some fat will be removed. If the patient has an appreciable tear trough deformity the author will remove the lateral fat pad, and reposition the nasal and central fat pads over the orbital rims.”

fat transfers with good results and without morbidity⁹. The placement of fat in the area of the tear trough should ideally be performed by practitioners experienced in the technique unless optimally placed lumps of fat will be visible through the relatively thin tissue of the eyelid and can only usually be removed surgically. Some practitioners are very skilled and do this routinely; while other skilled practitioners avoid using fat in this area.

The safe application of volume is dependent on proper technique and appreciation of the local anatomy. The author

usually injects HA fillers and fat in this facial area using blunt cannulas. It is the author's opinion that the cannulas result in less bruising and at least hypothetically provide more protection against an intravascular injection.

Blepharoplasty

Excess local soft tissue and laxity can be treated through various surgical techniques: blepharoplasty, blepharoplasty with fat repositioning, and various methods of midface lifting that can be performed transpalpebral as well as trans-temporal.

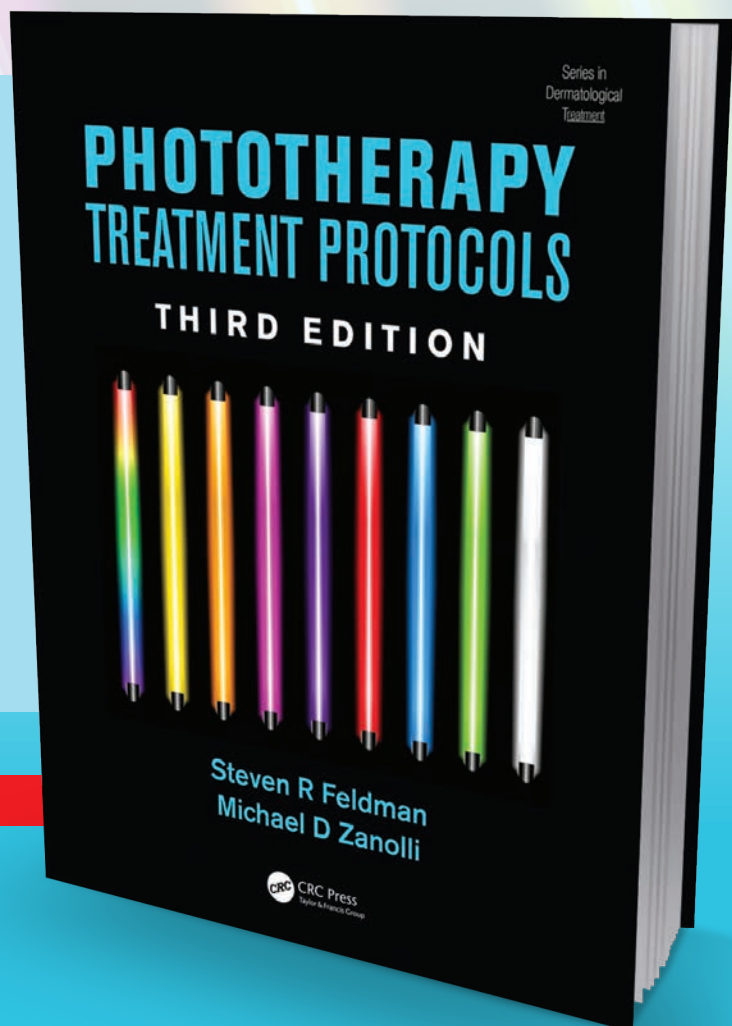
Blepharoplasty should be considered when there are more advanced aging changes in the region with skin excess of the eyelid, large amounts of fat pseudo-herniation, and lid malposition. There is a wide range of opinion of whether blepharoplasty is best performed via a transconjunctival or transcutaneous approach. The decision about approach is primarily made based on the patient's anatomy and previous history of blepharoplasty. The author's usual 'go-to' approach in most lower blepharoplasty procedures is a transconjunctival blepharoplasty with a skin pinch to remove skin excess. It is the author's opinion that this best preserves long-term orbicularis function. Most patients also undergo some form of canthopexy or resuspension of the orbicularis muscle.

If the plan is to perform a midface lift, correct a lid retraction, correct an ectropion or place an implant, the ▷

Third edition of bestselling manual of protocols for ultraviolet light therapy

- Written by experts with more than fifty years combined experience in the diagnosis and treatment of skin diseases, who have served as clinician, teacher, mentor and consultant.
- Provides technical information for UVB, PUVA, outpatient daycare, RePUVA, UVA/UVB combination, hand and foot therapy, scalp treatments, and hydrotherapy.
- Contains examples of patient education handouts, consent forms, laboratory flow sheets, forms for insurance companies, tools for the quantitative measurement of psoriasis severity, and more.
- Summarizes the actual details essential to clinical practice

June 2016 • 194pp • 9781498754620 • £38.99

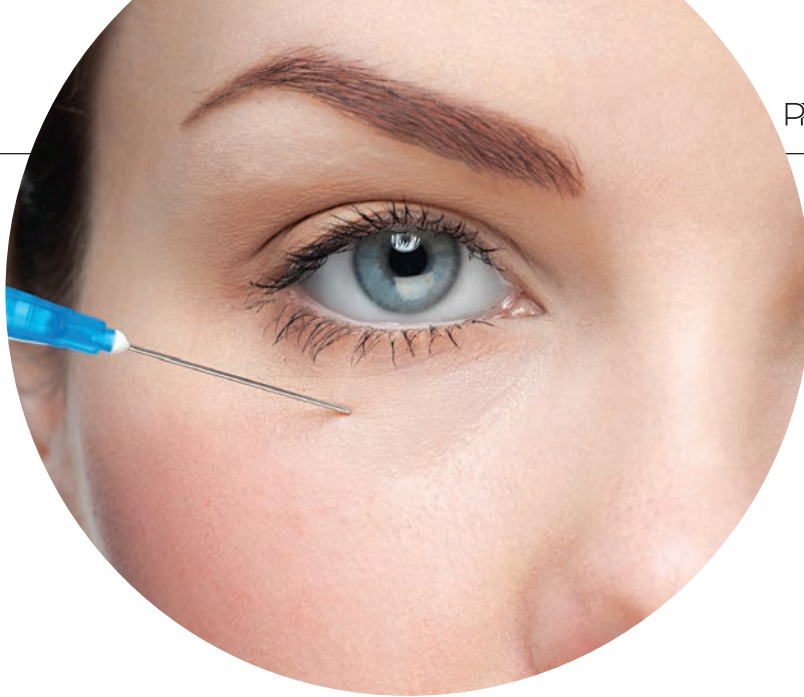

Order your copy today from
www.crcpress.com



CRC Press
Taylor & Francis Group

www.crcpress.com



“If the plan is to perform a midface lift, correct a lid retraction, correct an ectropion or place an implant, the author will at many times gravitate toward a transcutaneous blepharoplasty.”

endoscopic approach^{44,5}. Some midface lifting techniques are performed with blepharoplasty and can be done either through a transcutaneous or transconjunctival blepharoplasty approach¹⁶. The goals of the mid-facelift are to correct lower eyelid contour and position. They are also directed to improve the lid-cheek junction and to reposition the malar fat pad (*Figure 6*)¹⁷.

Skeletal correction

There are also a variety of custom implants available for the midface and the orbital rim made of several biocompatible materials¹⁸. In patients with lower eyelid malposition and a negative vector relationship, particularly if they have had a previous attempt at surgical correction, the author will augment the orbital rim with a solid orbital rim or malar implant. The author has experience with porous polyethylene and silastic implants that can be placed through transconjunctival or transcutaneous approaches. This is performed to correct the negative-vector skeletal abnormality (*Figure 7*).

In summary

Patients are now benefiting from the many advances for the correction of age-related concerns of the lower eyelid and midface. The ability to provide the early and initial correction of volume deficiencies has dramatically changed the approach to the area. When such volume corrections are coupled with other interventions, such as blepharoplasty and midface lifting, the spectrum of midface aging can be comprehensively approached and successfully improved.

► **Declaration of interest** None

► **Figures 1-7** © Fred Fedok

► author will at many times gravitate toward a transcutaneous blepharoplasty. The placement of the transcutaneous incisions is usually lower on the eyelid at a distance away from the ciliary line, i.e., at least 4 mm in order to preserve the pretarsal orbicularis. (The younger the patient, the closer the incision is placed towards the ciliary line.) The medial extent of the incision should be limited to preserve the buccal innervation of the orbicularis muscle.

Until the mid-90s, the surgical approach for the rejuvenation of the periorbital area was largely limited to lower blepharoplasty with resuspension of eyelid soft tissue, removal of excess skin, and removal of any bulge of orbital fat. There was a later modification of blepharoplasty developed by repositioning orbital fat over the orbital rim to serve as a biologic internal implant to camouflage the skeletonization of the orbital rim¹⁰⁻¹². What was initially hidden by the SOOF was now covered by the repositioned orbital fat.

If patients have a large amount of bulging orbital fat, some fat will be removed¹⁹. If the patient has an appreciable tear trough deformity, the author will remove the lateral fat pad, and reposition the nasal and central fat pads over the orbital rims.

Lifting the midface

There are a number of variations to the procedures described as midface lifts. Some of the more involved techniques are undertaken through a trans-temporal

Key points

- 1 Management of the midface has important aesthetic and functional implications
- 2 Interventions are chosen based on the anatomic problem
- 3 There are both surgical and nonsurgical options for correction of abnormalities
- 4 Off the shelf fillers have an important role
- 5 Skeletal abnormalities may be corrected with implants

References

1. Yousif NJ, Mendelson BC. Anatomy of the midface. *Clin Plast Surg*. Apr 1995; 22(2):227-240
2. Yousif NJ. Changes of the midface with age. *Clin Plast Surg*. Apr 1995;22(2):213-226
3. Levine RA. Aging of the midface bony elements. *Plast Reconstr Surg*. Jan 2008;121(1):337; author reply 337-338
4. Truswell WH. Aging changes of the periorbital, cheeks, and midface. *Facial Plast Surg*. Feb 2013;29(1):3-12
5. Baumann L, Narins RS, Beer K, et al. Volumizing Hyaluronic Acid Filler for Midface Volume Deficit: Results After Repeat Treatment. *Dermatol Surg*. Dec 2015;41 Suppl 1:S284-292
6. Glaser DA, Kenkel JM, Paradkar-Mitragotri D, Murphy DK, Romagnano L, Drinkwater A. Duration of effect by injection volume and facial subregion for a volumizing hyaluronic acid filler in treating midface volume deficit. *Dermatol Surg*. Aug 2015;41(8):942-949
7. Wilson MV, Fabi SG, Greene R. Correction of Age-Related Midface Volume Loss With Low-Volume Hyaluronic Acid Filler. *JAMA Facial Plast Surg*. Oct 20 2016
8. Few J, Cox SE, Paradkar-Mitragotri D, Murphy DK. A Multicenter, Single-Blind Randomized, Controlled Study of a Volumizing Hyaluronic Acid Filler for Midface Volume Deficit: Patient-Reported Outcomes at 2 Years. *Aesthet Surg J*. Jul 2015;35(5):589-599
9. Pontius AT, Williams EF, 3rd. The evolution of midface rejuvenation: combining the midface-lift and fat transfer. *Arch Facial Plast Surg*. Sep-Oct 2006;8(5):300-305
10. Jacono AA, Malone MH. Extended Submuscular Blepharoplasty With Orbitomalar Ligament Release and Orbital Fat Repositioning. *JAMA Facial Plast Surg*. Jan 01 2017;19(1):72-73
11. Yoo DB, Peng GL, Massry GG. Transconjunctival lower blepharoplasty with fat repositioning: a retrospective comparison of transposing fat to the subperiosteal vs supraperiosteal planes. *JAMA Facial Plast Surg*. May 2013;15(3):176-181
12. Goldberg RA, Edelstein C, Shorr N. Fat repositioning in lower blepharoplasty to maintain infraorbital rim contour. *Facial Plast Surg*. 1999;15(3):225-229
13. Aakalu VK, Putterman AM. Fat repositioning in lower lid blepharoplasty: the role of titrated excision. *Ophthalm Plast Reconstr Surg*. Nov-Dec 2011;27(6):462
14. Williams EF, 3rd, Vargas H, Dahiya R, Hove CR, Rodgers BJ, Lam SM. Midfacial rejuvenation via a minimal-incision brow-lift approach: critical evaluation of a 5-year experience. *Arch Facial Plast Surg*. Nov-Dec 2003;5(6):470-478
15. Quatela VC, Choe KS. Endobrow-midface lift. *Facial Plast Surg*. Aug 2004;20(3):199-206
16. Sclafani AP, Dibellius G. Transpalpebral midface lift. *Facial Plast Surg Clin North Am*. May 2015;23(2):209-219
17. Keller G, Quatela VC, Antunes MB, Sykes JM, Magill CK, Seth R. Midface lift: panel discussion. *Facial Plast Surg Clin North Am*. Feb 2014;22(1):119-137
18. Weinberg DA, Goldberg RA, Hoenig J, Shorr N, Baylis HI. Management of relative proptosis with a porous polyethylene orbital rim onlay implant. *Ophthalm Plast Reconstr Surg*. Jan 1999;15(1):67-73